



# A novel high-power 1060-nm diode laser for the treatment of vascular malformations: a pilot study using dermoscopy to evaluate clinical endpoints

Diego Fernandez-Nieto<sup>1</sup> · Juan Jimenez-Cauhe<sup>1</sup> · Daniel Ortega-Quijano<sup>1</sup> · Pablo Boixeda<sup>1</sup>

Received: 13 February 2020 / Accepted: 9 June 2020  
© Springer-Verlag London Ltd., part of Springer Nature 2020

## Introduction

Vascular malformations are a type of vascular anomalies that lack a proliferative component, in contrast to vascular tumors. Vascular malformations, which are due to inborn errors in vascular morphogenesis, are classified into capillary, venous, lymphatic, arterial, and combined malformations [1]. Therapy for vascular malformations remains challenging. Due to its good safety/efficacy profile, pulsed dye laser (PDL) is a well-established treatment for capillary malformations [2]. However, many capillary malformations respond well to initial PDL treatments but become less responsive to following ones, with complete response rates around 20%. The limited penetration depth of PDL prevents the treatment of large ectatic vessels located in deep skin layers [3]. Other low-flow vascular malformations, including venous malformations, present the same problem. The 1064-nm long-pulsed neodymium:yttrium-aluminum-garnet (LP-Nd:YAG) laser has been widely used for the treatment of venous malformations and also PDL-resistant capillary malformations. The 755-nm alexandrite laser is also another option for resistant capillary malformations, especially dark, hypertrophic port wine stains [4]. The 1060-nm high-power diode laser can also be an alternative treatment of vascular malformations.

The 1060-nm range is considered to provide a good hemoglobin/melanin absorption ratio, making it feasible for the different Fitzpatrick skin types. Photothermolysis of microvessels can penetrate deeper with a 1060 nm than with a 595-nm or a 755-nm wavelength, thus en-

hancing results [5]. The 755-nm alexandrite laser yields better results than the PDL in the treatment of hypertrophic, purple port wine stains, with a higher risk of permanent dyspigmentation because of a higher melanin absorption [3]. The 1064-nm LP-Nd:YAG laser is more effective and also safer for III–V skin types, although the therapeutic window is narrower since it is less specific for hemoglobin than PDL or alexandrite lasers and has a higher rate of dermal scattering. Permanent scarring can occur, especially with higher wavelengths. Epidermal cooling, observation of clinical endpoints, and dosimetry adjustments are essential to minimize risks [6]. For vascular malformations, in most cases, a transient gray color that immediately evolves to deep purpura is the optimal endpoint. An immediate metallic gray blanching correlates with non-specific dermal injury and a higher risk of post-procedural scarring [6].

The 1060-nm diode laser has been successfully used for the treatment of hair removal [7] and laser lipolysis [8, 9]. However, in the field of vascular malformations, there is only one case series for the treatment of cherry angiomas and venulectasias [10]. The main limitation of the 1060-nm diode laser compared to classic 1064-nm LP-Nd:YAG is that it cannot reach such high fluences. However, this can be compensated by using multiple pulses.

## Objective

The aim of this study is to evaluate the efficacy and safety of a 1060-nm high-power diode laser in the treatment of vascular malformations, including capillary and venous malformations. We aimed to select the most adequate parameters in every case depending on the patient and the characteristics of the lesion.

✉ Diego Fernandez-Nieto  
fnietodiego@gmail.com

<sup>1</sup> Dermatology Department, Ramon y Cajal University Hospital, Carretera Colmenar Viejo km 9.100, 28034 Madrid, Spain

## Material and methods

We designed a prospective study of 12 patients affected of vascular malformations treated with a 1060-nm high-power diode laser (Primelase Excellence and  $10 \times 10$  mm<sup>2</sup>-1060 nm-4000 W applicator, cocoon medical, Barcelona, Spain) at our hospital. Efficacy was evaluated by two blinded dermatologists at the end of the treatment by a score system, in which size reductions of 0–25%, 25–50%, 50–75%, and 75–100%, of the lesion, were respectively assigned a score from 0 to 3. Statistical analysis of the results was performed using the SPSS 15.0 statistical software (SPSS). Procedure consisted on the application of 1060-nm diode laser every 6 weeks using the following parameters:  $10 \times 10$ mm spot size, 7 to 10 ms pulse duration, 25 to 35 J/cm<sup>2</sup> fluence, 1 to 4 stacks with 250 ms delay. The laser irradiation follows a square top-hat spatial pattern, which is the main distribution profile of the laser diodes. The energy is evenly distributed over its entire area. Epidermal cooling was provided with contact cooling by the 10 °C cold sapphire tip of the applicator, 3 s before shooting. All the patients received topical anesthetic (lidocaine and prilocaine) 1 h before the procedure. All the patients received a “test session” to select the most adequate parameters before the final treatment, attending to clinical and dermoscopic endpoints. Clinical endpoint was permanent purpura, in the absence of epidermal frosting. Reaching a dermoscopic endpoint of 50% purpura or vessel disappearance was considered as adequate.

## Results

Table 1 summarizes clinical and epidemiological characteristics of the patients.

Mean age of patients was 41.7 years (range 22–62); 5 patients (41.7%) were female. Mean score for efficacy was 2.3 (range 1–3) with a mean number of 1.2 sessions per patient (range 1 to 2). Of the 12 patients, 2 (16.7%) achieved less than 25% reduction in size, 4 (33.3%) achieved between 50 and 75%, and 6 (50%) between 75 and 100%. Seven patients (58.3%) had been previously treated with 595-nm PDL laser. Wilcoxon signed rank test showed statistical difference between the size of the lesions before and after laser treatment ( $p < 0.002$ ).

We selected a 50% immediate vessel purpura (or disappearance) as the adequate dermoscopic endpoint needed (Figs. 1, 2, 4). Venous malformations had a size reduction of more than 75% in 4 of 5 patients (80%) (Fig. 3), with optimal results at the following parameters: 22 J/cm<sup>2</sup>, 10 ms, stack 4, 250 ms delay (Fig. 4).

Adverse events were reported in 4 patients, including transient hypopigmentation in 3 patients (25%) and mild scarring with hypopigmentation in 1 patient (8.3%) during a 6-months follow-up.

## Discussion

The 1060-nm high-power diode laser is a semiconductor laser that provides similar parameters to solid-state lasers. This device is approved for the removal of vascular lesions under directive 93/42/EEC for medical devices by the notified body N°0051 and certificate number 1604/MDD revised and approved on 08/2019, although it is mainly used for hair removal and the treatment of active acne.

Other high-intensity diode lasers have been previously used in the treatment of vascular malformations, including 800, 810, 830, 940, and 980-nm wavelengths [11–17]. Diode-laser devices have a significantly lower cost than other high-power lasers, with unique intrinsic characteristics (contact cooling, high-shooting frequency, minimum maintenance). The PDL laser (595 nm) and the LP-Nd:YAG (1064 nm or 532 nm) are the most commonly used lasers in the treatment of vascular malformations, because of their safe profiles and wide areas of clinical use [18]. The 755 nm alexandrite laser has also been tried, alone or in combination with PDL [19].

In the past, semiconductor-based lasers were unable to emit large amounts of energy in short-pulse durations (in the milliseconds range). This barrier has supposed a technological constraint for diode lasers in comparison to solid-state lasers for the treatment of vascular lesions, until now. Indeed, for pulse durations shorter than 50 ms, semiconductor-based lasers do not reach as higher fluences as solid-state lasers.

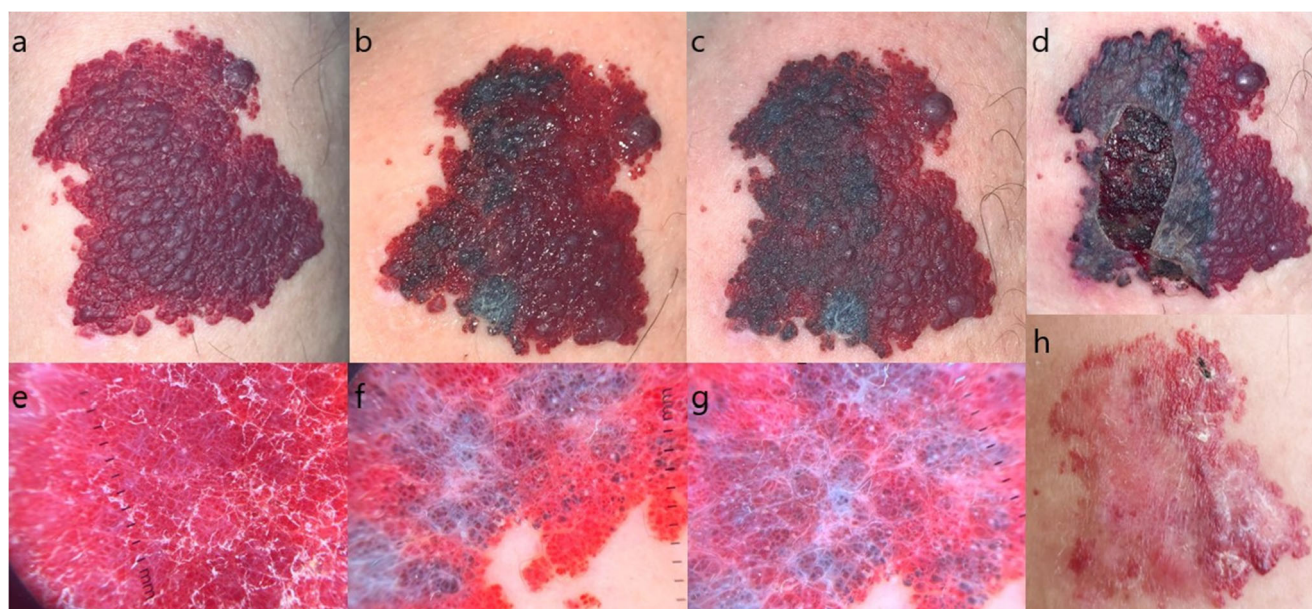
There are several feasible parameters for the treatment of vascular malformations. High fluence parameters (100–150 J/cm<sup>2</sup>) are available at the cost of relatively long pulse durations (60–80 ms), thus emulating the 1064nm LP-Nd:YAG laser [10]. Long pulse parameters can provide better efficacy, at the cost of an increased risk of adverse effects when compared to short-pulse parameters. Attending to Verkruysse et al. [20], multiple laser pulses (MLP) can significantly increase the targeted blood vessel temperature, due to cumulative heat propagation from adjacent vessels being treated simultaneously. MPL can achieve similar thermal effects with lower energy density than in single pulse treatments. Since lower energy density is applied, there is less energy absorbed by the epidermis, decreasing the risk for adverse events. MPL treatments have been widely reported in experimental models [21–23] and in patients with capillary malformations [24]. MPL treatments allow selective photothermolysis of deep-lying vessels and also thick vessels, which are commonly present in laser-resistant capillary malformations [25].

We used clinical and dermoscopic immediate post-treatment endpoints to select the most appropriate parameters for MPL treatment. Clinical purpura as a therapeutic endpoint has been widely used in the treatment of vascular malformations, correlating with therapeutic response. However, potential pitfalls can occur depending on the vascularization pattern, especially at long pulse durations [26], with

**Table 1** Clinical and epidemiological characteristics of the patients

Patient	Age, sex, phototype*	Vascular lesion, localization	Diameter (cm)	Number of sessions	Clinical improvement	Selected parameters	Adverse events	Previous PDL treatment
1	22, M, II	Capillary malformation (serpiginous angioma), left arm	12 × 4	1	2	35 J/cm <sup>2</sup> , 10 ms, stack 4	Transient hypopigmentation	Yes, 3 sessions
2	23, F, III	Capillary malformation, right arm	9 × 4.2	2	2	35 J/cm <sup>2</sup> , 10 ms, Stack 3	No	Yes, 1 session
3	29, F, II	Venous malformation, left shoulder	0.8 × 0.7	1	2	22 J/cm <sup>2</sup> , 6 ms, stack 3	No	No
4 (Fig. 1)	32, M, III	Hypertrophic capillary malformation, right arm	3 × 1.5	1	2	35 J/cm <sup>2</sup> , 10 ms, Stack 2	Mild scarring with permanent hypopigmentation	Yes, 3 sessions
5	40, F, II	Venous malformation, lower lip	3.5 × 2.2	1	3	22 J/cm <sup>2</sup> , 6 ms, stack 4	No	No
6	41, M, III	Venous malformation, lower lip	0.3 × 0.3	1	3	22 J/cm <sup>2</sup> , 6 ms, stack 4	No	No
7 (Fig. 2)	42, M, II	Hypertrophic capillary malformation, face	1.2 × 0.8	1	3	35 J/cm <sup>2</sup> , 10 ms, stack 3	No	Yes, 2 sessions
8	44, F, III	Multiple venous malformations, back, neckline	0.7 × 0.5, 0.8 × 0.6, 1 × 0.9, 0.6 × 0.5	1	3	35 J/cm <sup>2</sup> , 10 ms, Stack 4	Transient hypopigmentation	Yes
9	52, F, III	Extensive capillary malformation, right arm	42 × 12	2	1	25 J/cm <sup>2</sup> , 7 ms, stack 4	Transient hypopigmentation	Yes, 5 sessions
10	56, M, III	Rendu Osler-Weber syndrome: facial capillary telangiectasias	0.1 (n = 18)	1	1	25 J/cm <sup>2</sup> , 7 ms, stack 3	No	Yes, 3 sessions
11 (Fig. 3)	57, M, III	Venous malformation, upper lip	0.6 × 0.5	1	3	22 J/cm <sup>2</sup> , 6 ms, stack 4	No	No
12 (Fig. 4)	62, M, III	Cherry angiomas, chest	0.6 × 0.5, 0.5 × 0.5, 0.3 × 0.3, 0.2 × 0.2	1	3	30 J/cm <sup>2</sup> , 10 ms, stack 4	No	No

\*Fitzpatrick skin type

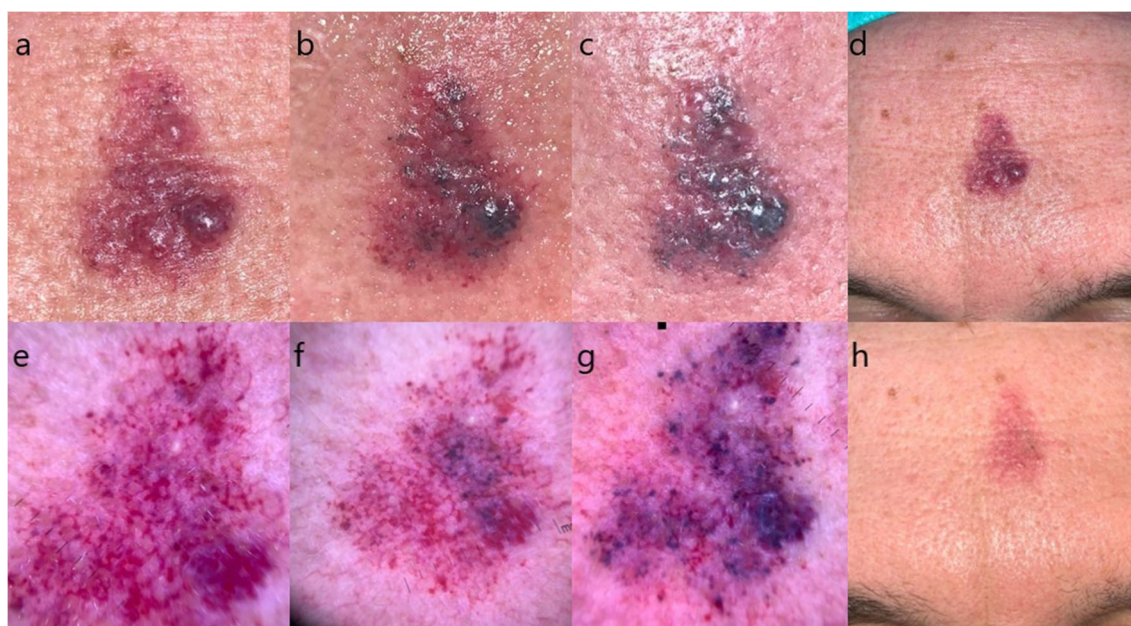


**Fig. 1** Patient 4, hypertrophic capillary malformation treated with Primelase Excellence and  $10 \times 10$  mm<sup>2</sup>-1060 nm-4000 W applicator, cocoon medical, Barcelona, Spain. From left to right, clinical presentation (a), after 1 pulse (35 J/cm<sup>2</sup>, 10 ms) of split-treatment (b), and after 2 pulses (c). An epidermal detachment can be observed in the 7-day visit (d). Dermoscopic evaluation shows grouped red dots and

globules surrounded by fibrous tracts (e). After 1 pulse, 35% is achieved (f). After 2 pulses, 70% of purpura is achieved (g). Clinical response shows the difference between 2 pulses (35 J/cm<sup>2</sup>, 10 ms) in the left side and only 1 pulse (35 J/cm<sup>2</sup>, 10 ms) in the right side. Clinical improvement is observed after 1 session, including a mild scarring (h)

an increased risk of complications. Dermoscopy is a useful tool to select the minimal fluence required. The selected endpoint, immediate post-irradiation vessel purpura or

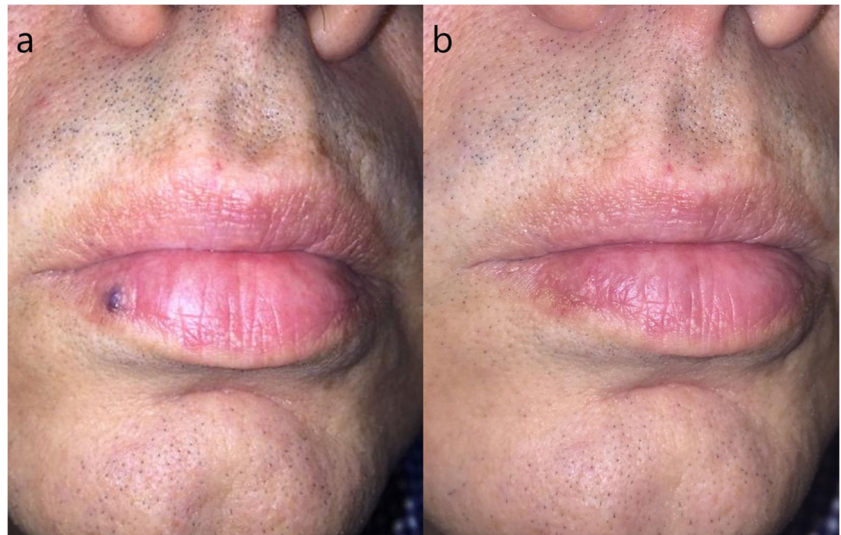
disappearance (detected by dermoscopy), correlates with the therapeutic outcome. This is especially useful in the treatment of vascular malformations with deep vessels, when clinical



**Fig. 2** Patient 4, hypertrophic capillary malformation treated with Primelase Excellence and  $10 \times 10$  mm<sup>2</sup>-1060 nm-4000 W applicator, cocoon medical, Barcelona, Spain. From left to right, clinical presentation (a), after 1 pulse (35 J/cm<sup>2</sup>, 10 ms) (b), and after 3 pulses (c). Dermoscopic examination shows a network of red linear vessels

horizontally oriented and red to blue globules and lakes (e). After 1 pulse, a 25% of purpura is achieved (f). After 3 pulses, a 65% of purpura is achieved (g). Clinical improvement can be observed in a 6-week period after 1 session (from d to h)

**Fig. 3** Patient 7, venous malformation treated with Primelase Excellence and  $10 \times 10$  mm<sup>2</sup>-1060 nm-4000 W applicator, cocoon medical, Barcelona, Spain. Clinical presentation (a), treated with following parameters: 22 J/cm<sup>2</sup>, 6 msec, stack 4, 250 ms delay. Results at the 6-week follow-up after 1 session (b)



purpura may not be achieved [26]. However, in most cases there is a positive correlation between clinical and dermoscopic endpoints [27].

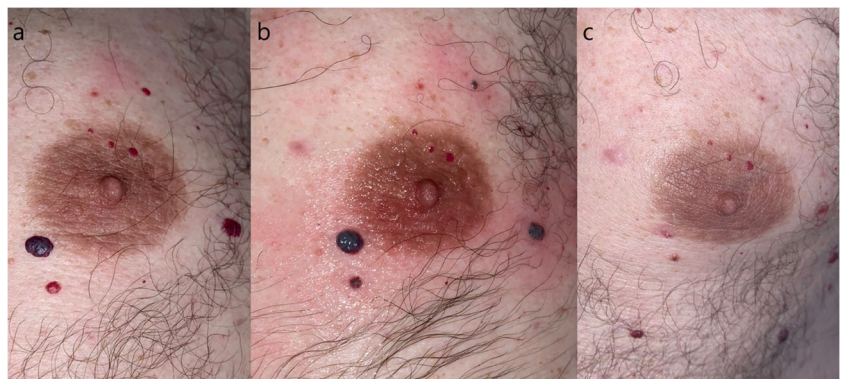
Fluences varied between 20 to 35 J/cm<sup>2</sup> (with a maximum pulse duration of 10 ms). Depending on the lesion and patient characteristics, we noticed that 22–35 J/cm<sup>2</sup> at stack 3 or 4 is sufficient in general terms to the treatment of vascular malformations, providing a good balance between efficacy and safety results and thus preventing the risks of long single pulse treatments. In our experience, the most convenient dermoscopic endpoint for a single session is around 50% of purpura or vessel disappearance. Trying to achieve a higher rate in PDL-resistant capillary malformations could result in permanent scarring, as it can be seen in Fig. 1 where a 70% of purpura was obtained. Hypopigmentation after the procedure recovered in less than 6 weeks in the three patients. This is a common side effect to laser treatment that can be permanent, but it is more common in lasers with a higher melanin absorption like alexandrite laser and QS-Nd:YAG laser, [28, 29].

Due to high fluences and relatively long pulse durations, this treatment can cause moderate pain. Local anesthesia is recommended to minimize discomfort. Regarding post-treatment care, avoiding sun exposure for between 10 and 15 days is recommended, even with SPF 50 protection. If additional sessions are required, it is recommended that at least 45 days are allowed to elapse following the previous session.

Like the 1064 nm LP-Nd:YAG, this laser should be avoided for treating children and pale-red to pink capillary malformations. Venous malformations respond particularly well to this treatment.

The main limitation of this pilot study is the variability between types of vascular malformations and relatively low number of treated patients. We cannot categorically affirm that the results obtained with the 1060-nm high-power diode laser are comparable with the 1064 nm LP-Nd:YAG. However, it appears that a good response rate can be obtained, with also a low incidence of adverse effects. More well-designed controlled studies are needed to

**Fig. 4** Patient 12, cherry angiomas treated with Primelase Excellence and  $10 \times 10$  mm<sup>2</sup>-1060 nm-4000 W applicator, cocoon medical, Barcelona, Spain. Clinical presentation (a), immediately after the treatment (30 J/cm<sup>2</sup>, 10 ms, stack 4, 250 ms delay) (b), and at the 6-week follow-up after 1 session (c)



characterize optimal parameters of laser treatment, including a LP-Nd:YAG control arm.

## Conclusions

The 1060-nm high-power diode laser appears to be a safe and effective alternative for the treatment of vascular malformations. Further studies are required to support this conclusion.

Dermoscopy is a useful auxiliary tool that can help the clinician to adjust laser settings. Immediate purpura detected by dermoscopy appears to correlate with the therapeutic outcome.

**Role of funding source** Cocoon Medical® had no role in the design of this study and did not have any role during its execution, analyses, interpretation of the data, or decision to submit results.

## Compliance with ethical standards

**Human and animal rights and informed consent** All human and animal studies are approved by an Institutional Review Board. Informed consent was obtained from all individual participants included in the study.

**Conflict of interest** The high-power 1060 nm diode laser was provided by Cocoon Medical® for the elaboration of this study.

**Ethical approval** This study was approved by the Research Ethics Committee of our center.

## References

- Wassef M, Blei F, Adams D et al (2015) Vascular anomalies classification: recommendations from the International Society for the Study of Vascular Anomalies. *Pediatrics* 136:e203–e214 <https://doi.org/10.1542/peds.2014-3673>
- Murthy AS, Dawson A, Gupta D et al (2017) Utility and tolerability of the long-pulsed 1064-nm neodymium:yttrium-aluminum-garnet (LP Nd:YAG) laser for treatment of symptomatic or disfiguring vascular malformations in children and adolescents. *J Am Acad Dermatol* 77:473–479 <https://doi.org/10.1016/j.jaad.2017.04.014>
- Li D, Zhang H, Chen B, et al (2020) Experimental investigations on thermal effects of a long-pulse alexandrite laser on blood vessels and its comparison with pulsed dye and Nd:YAG lasers. *Lasers Med Sci*. <https://doi.org/10.1007/s10103-020-02981-9>
- Grillo E, González-Muñoz P, Boixeda P et al (2016) Alexandrite laser for the treatment of resistant and hypertrophic port wine stains: a clinical, histological and histochemical study. *Actas Dermosifiliogr* 107:591–596 <https://doi.org/10.1016/j.ad.2016.04.016>
- van Drooge AM, Bosveld B, van der Veen JPW et al (2013) Long-pulsed 1064 nm Nd:YAG laser improves hypertrophic port-wine stains. *J Eur Acad Dermatol Venereol* 27:1381–1386 <https://doi.org/10.1111/jdv.12021>
- Wanner M, Sakamoto FH, Avram MM, Anderson RR (2016) Immediate skin responses to laser and light treatments: warning endpoints: how to avoid side effects. *J Am Acad Dermatol* 74: 807–819; quiz 819–820 <https://doi.org/10.1016/j.jaad.2015.06.025>
- Ross EV, Ibrahim OA, Kilmer S (2018) Long-term clinical evaluation of hair clearance in darkly pigmented individuals using a novel diode 1060 nm wavelength with multiple treatment handpieces: a prospective analysis with modeling and histological findings. *Lasers Surg Med* 50:893–901 <https://doi.org/10.1002/lsm.22943>
- Schilling L, Saedi N, Weiss R (2017) 1060 nm diode hyperthermic laser lipolysis: the latest in non-invasive body contouring. *J Drugs Dermatol* 16:48–52
- Bass LS, Doherty ST (2018) Safety and efficacy of a non-invasive 1060 nm diode laser for fat reduction of the abdomen. *J Drugs Dermatol* 17:106–112
- Bordera GB, Parada JG, Giménez MM et al (2019) Use of high-power diode laser at 1060 nm for the treatment of vascular lesions. *J Vasc Surg Cases Innov Tech* 5:415–418 <https://doi.org/10.1016/j.jvscit.2019.06.015>
- Capodiferro S, Limongelli L, Tempesta A et al (2018) Diode laser treatment of venous lake of the lip. *Clin Case Rep* 6:1923–1924 <https://doi.org/10.1002/ccr3.1735>
- Azevedo LH, Del Vecchio A, Nakajima E et al (2013) Lip and oral venous varices treated by photocoagulation with high-intensity diode laser. *Quintessence Int* 44:171–174 <https://doi.org/10.3290/j.ia.28926>
- Wollina U (2016) Three hundred patients treated with ultrapulsed 980 nm diode laser for skin disorders. *Indian J Dermatol* 61:540–544 <https://doi.org/10.4103/0019-5154.190111>
- Favia G, Limongelli L, Tempesta A et al (2015) PHACES syndrome: diode laser photocoagulation of intraoral hemangiomas in six young patients. *Int J Surg Case Rep* 11:124–128 <https://doi.org/10.1016/j.ijscr.2015.03.045>
- Danesh MJ, Vazimia A, Anderson RR (2019) Diode laser for the use of lingual venous malformations. *J Am Acad Dermatol*. <https://doi.org/10.1016/j.jaad.2019.11.043>
- Bacci C, Sacchetto L, Zanette G, Sivoletta S (2018) Diode laser to treat small oral vascular malformations: a prospective case series study. *Lasers Surg Med* 50:111–116 <https://doi.org/10.1002/lsm.22737>
- Dementieva N, Jones S (2016) The treatment of problematic hemangiomas in children with propranolol and 940nm diode laser. *J Pediatr Surg* 51:863–868 <https://doi.org/10.1016/j.jpedsurg.2016.02.038>
- Gianfaldoni S, Tchernev G, Wollina U et al (2017) An overview of laser in dermatology: the past, the present and ... the future (?). *Open Access Maced J Med Sci* 5:526–530 <https://doi.org/10.3889/oamjms.2017.130>
- Baumgartner J, Šimaljaková M, Babál P (2016) Extensive angiokeratoma circumscriptum - successful treatment with 595-nm variable-pulse pulsed dye laser and 755-nm long-pulse pulsed alexandrite laser. *J Cosmet Laser Ther* 18:134–137 <https://doi.org/10.3109/14764172.2015.1114643>
- Verkruysse W, van Gemert MJ, Smithies DJ, Nelson JS (2000) Modelling multiple laser pulses for port wine stain treatment. *Phys Med Biol* 45:N197–N203 <https://doi.org/10.1088/0031-9155/45/12/403>
- Jia W, Tran N, Sun V et al (2012) Photocoagulation of dermal blood vessels with multiple laser pulses in an in vivo microvascular model. *Lasers Surg Med* 44:144–151 <https://doi.org/10.1002/lsm.22000>
- Li D, Li R, Jia H et al (2017) Experimental and numerical investigation on the transient vascular thermal response to multi-pulse Nd:YAG laser. *Lasers Surg Med* 49:852–865 <https://doi.org/10.1002/lsm.22695>
- Ma J, Chen B, Li D et al (2018) Glucose in conjunction with multiple laser pulses on laser treatment of port-wine stain: an in vivo study. *Lasers Med Sci* 33:1295–1306 <https://doi.org/10.1007/s10103-018-2481-1>
- Aldanondo I, Boixeda P, Fernández-Lorente M et al (2008) Selectivity of photothermolysis in the treatment of port wine stains

- using multiple pulses with a pulsed dye laser. *Actas Dermosifiliogr* 99:546–554
25. Savas JA, Ledon JA, Franca K et al (2013) Pulsed dye laser-resistant port-wine stains: mechanisms of resistance and implications for treatment. *Br J Dermatol* 168:941–953 <https://doi.org/10.1111/bjd.12204>
  26. Abdul Latif AA, Abdel-Hameed AKS, Salama OAAM (2019) Immediate post-irradiation dermoscopic vascular changes versus purpura as a therapeutic endpoint in pulsed-dye laser treatment of port wine stains. *Dermatol Ther* 32:e13094 <https://doi.org/10.1111/dth.13094>
  27. Shirakawa M, Ozawa T, Wakami S et al (2012) Utility of dermoscopy before and after laser irradiation in port wine stains. *Ann Dermatol* 24:7–10 <https://doi.org/10.5021/ad.2012.24.1.7>
  28. Weisberg NK, Greenbaum SS (2003) Pigmentary changes after alexandrite laser hair removal. *Dermatol Surg* 29:415–419 <https://doi.org/10.1046/j.1524-4725.2003.29098.x>
  29. Chan HH, Leung RS, Ying SY et al (2000) A retrospective analysis of complications in the treatment of nevus of Ota with the Q-switched alexandrite and Q-switched Nd:YAG lasers. *Dermatol Surg* 26:1000–1006 <https://doi.org/10.1046/j.1524-4725.2000.0260111000.x>

**Publisher's note** Springer Nature remains neutral with regard to jurisdictional claims in published maps and institutional affiliations.